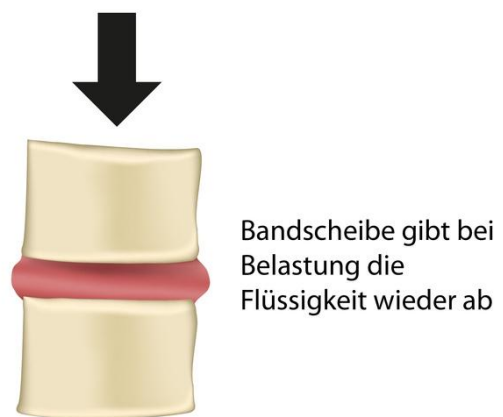
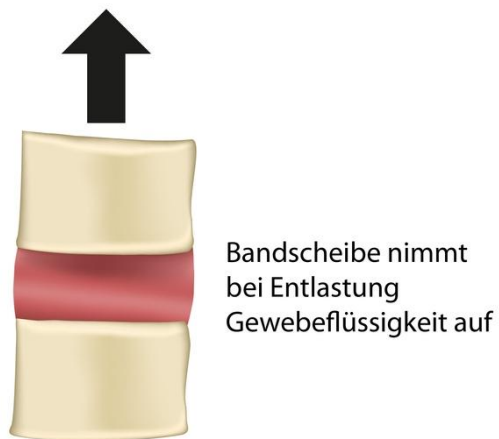
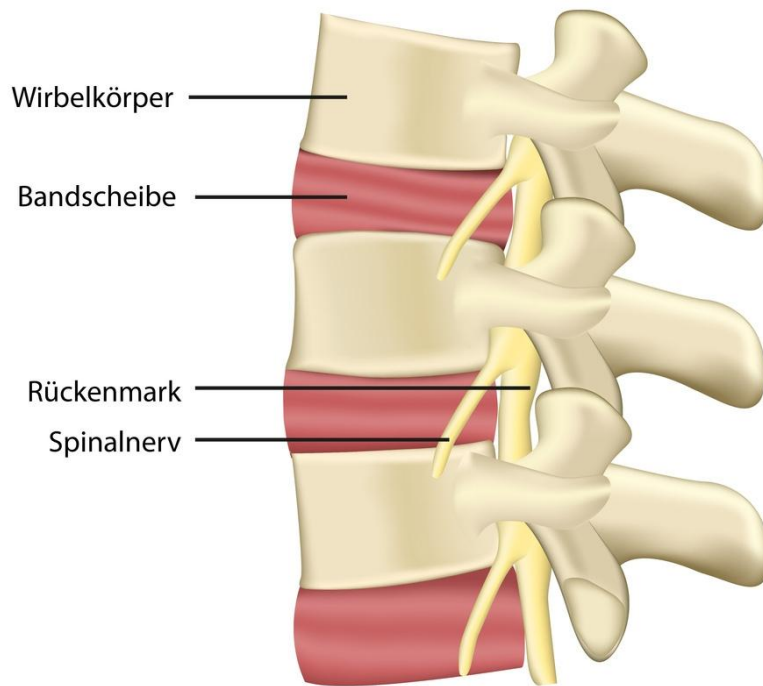


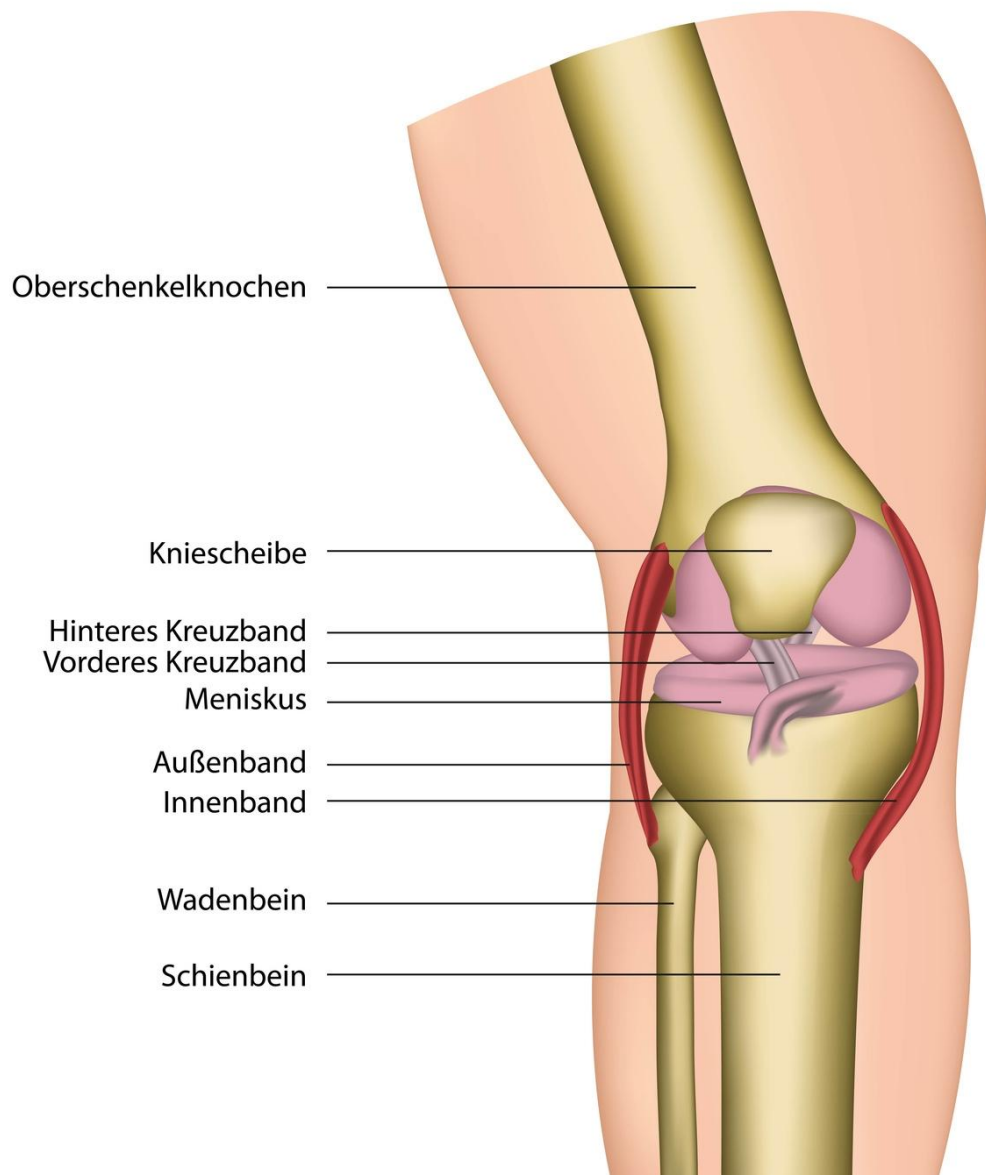
Wirbelsäule



© bilderzweg – Fotolia.com

<http://www.aok-bw.de/orthopaedie>

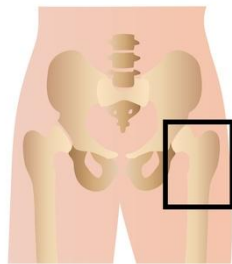
Kniegelenk



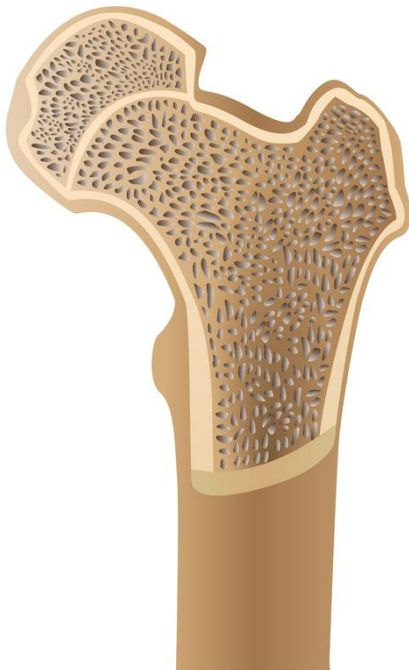© bilderzweg – Fotolia.com

<http://www.aok-bw.de/orthopaedie>

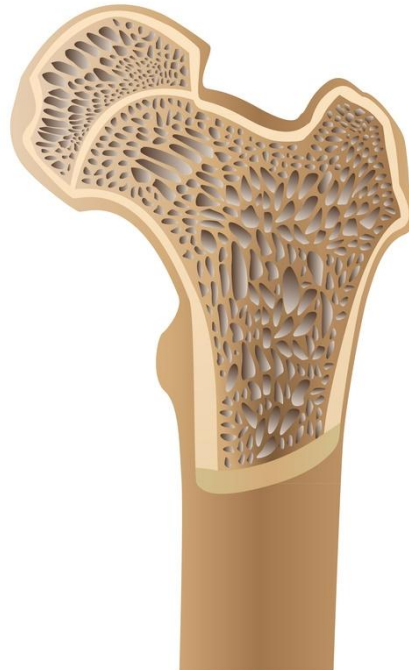Osteoporose



Osteoporose (Knochenschwund)



Normaler Knochen

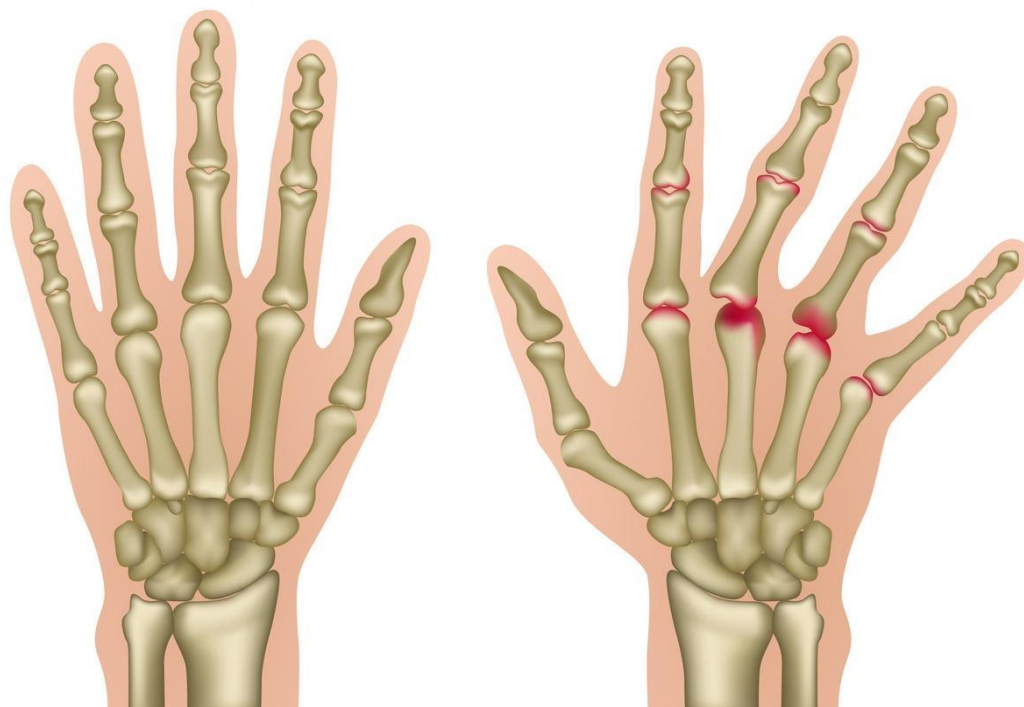


Knochen mit
Osteoporose

© bilderzweig – Fotolia.com

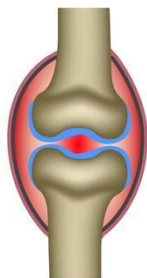
<http://www.aok-bw.de/orthopaedie>

Rheumatoide Arthritis

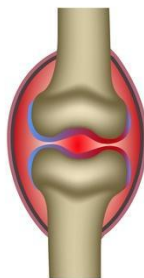


Gesunde Knochen

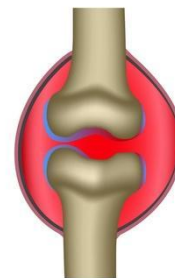
Hand mit rheumatoider Arthritis



1. Gelenkentzündung



2. An der Gelenkinnenhaut entsteht ein geschwülstartiges Gewebe.



3. Knorpel und Knochen werden mit der Zeit zerstört. Die Gelenkkapsel schwillt an.

© bilderzweig – Fotolia.com